2 Causes rares d'AVC hémorragiques

Prof. Guillaume SALIOU, MD, PhD
Neuroradiologie interventionnelle - CHUV

2 Cause Rares et urgences thérapeutiques

- Artérielle : Embolie septique et « faux » anévrisme mycotique
- Veineuse : Thrombose veineuse cérébrale maligne

guillaume.saliou@chuv.ch

Rupture de faux anévrisme mycotique

guillaume.saliou@chuv.ch



guillaume.saliou@chuv.ch

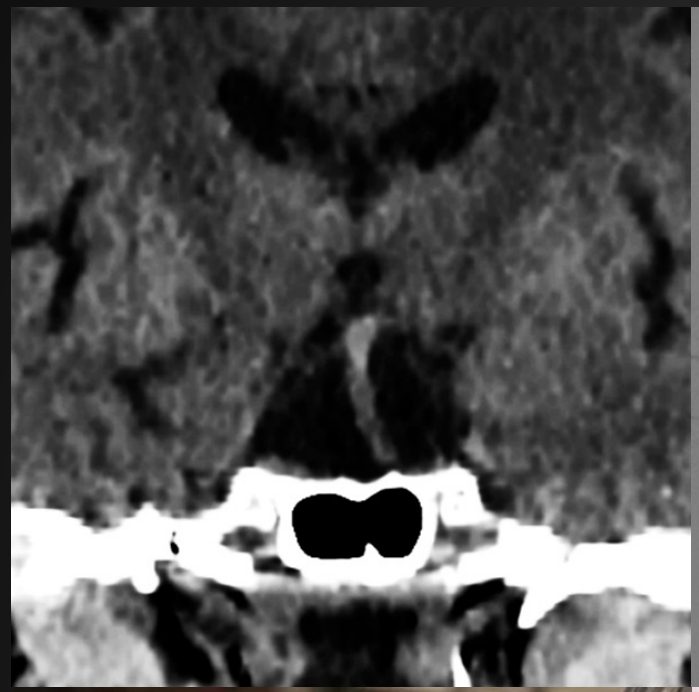

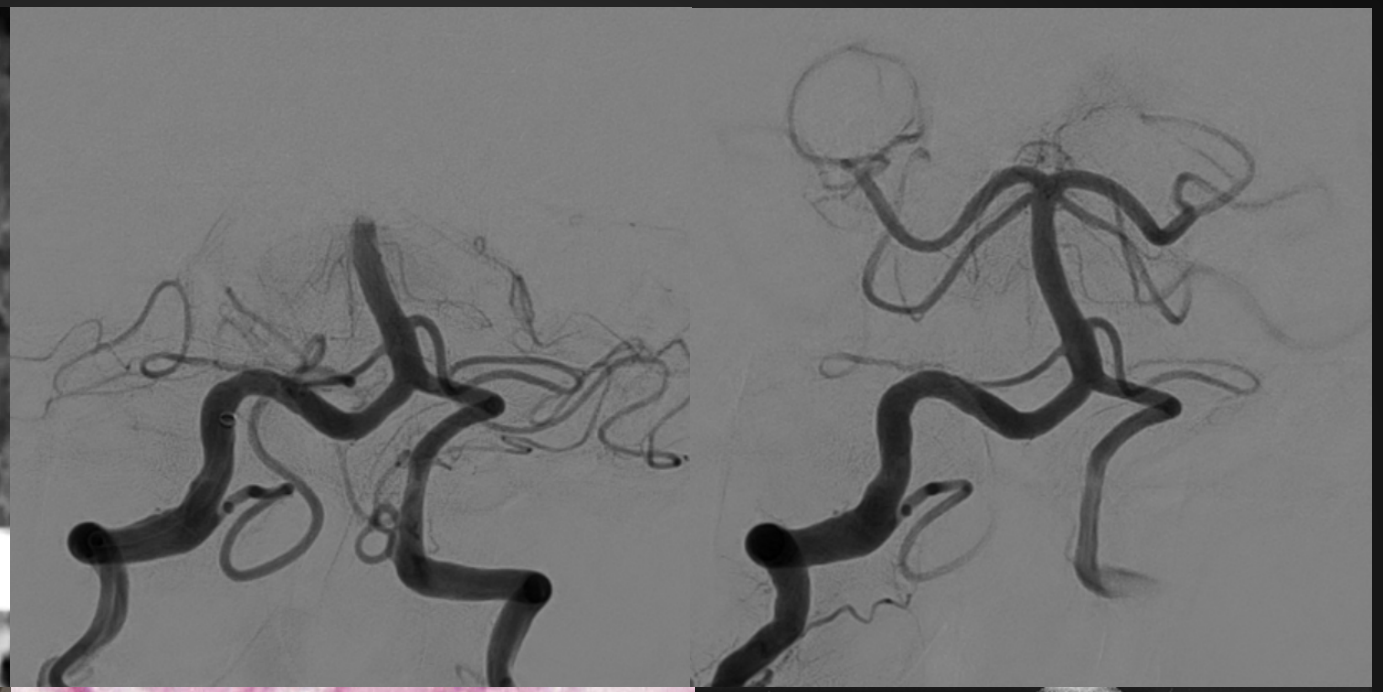

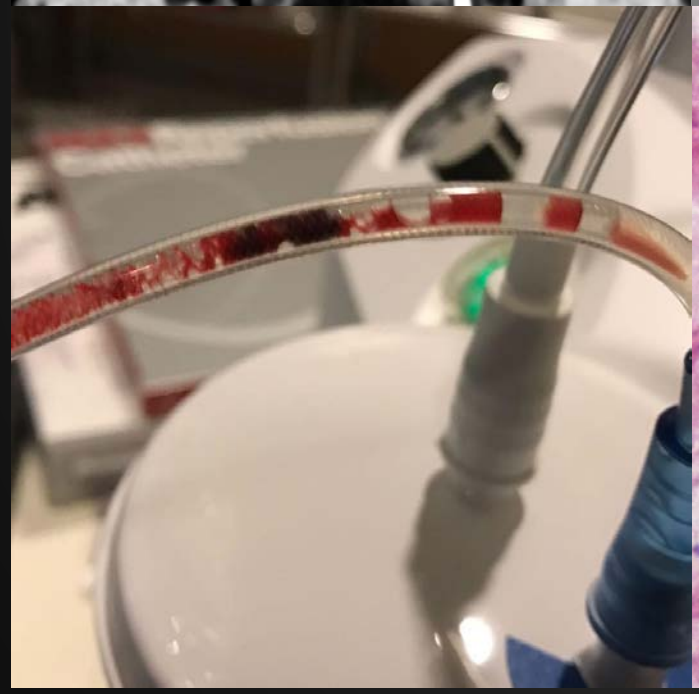

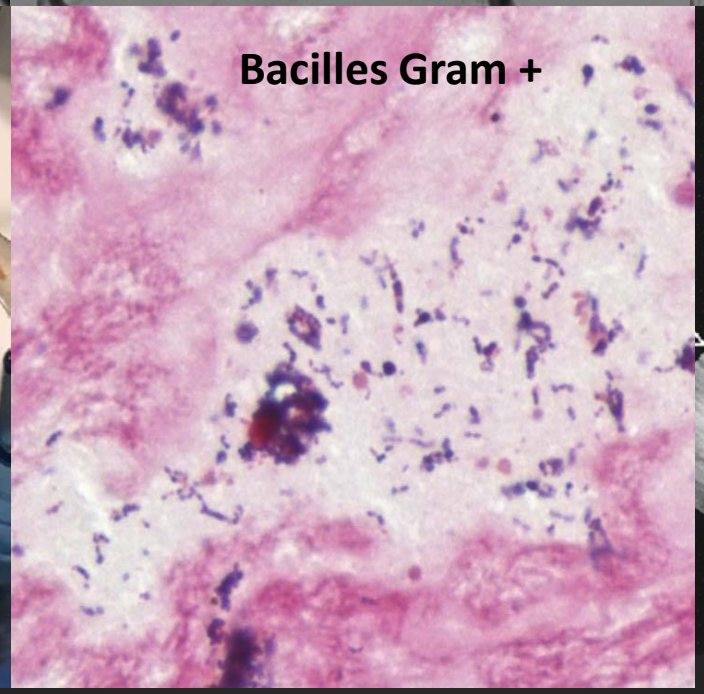
Bacilles Gram +

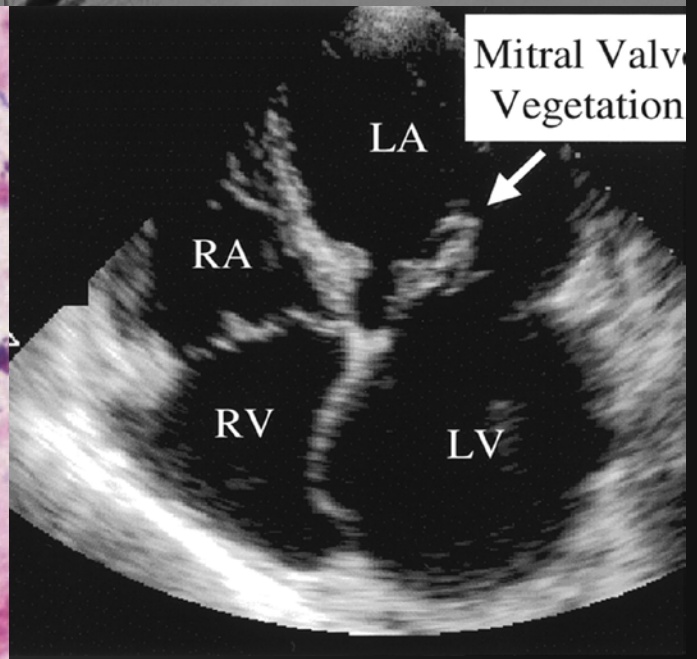
Mitral Valve
Vegetation
LA
RA
RV
LV

« Faux » ou « pseudo » anévrisme mycotique

- Multiples dans 15-25%
- Carotide >> vertébro-basilaire
- <5% des anévrismes de l’adulte
- 15% des anévrisme pédiatriques !

guillaume.saliou@chuv.ch

Présentation

- Non Rompu : 30% de mortalité
  - Céphalées : 30%
  - Fièvre : 28%
  - Hémiparésie : 15%
  - Vomissement : 9%
- Rompu : 80% de mortalité
  - Id rupture d'anévrismes non mycotiques
  - Risque de re-saignement >> anévrismes non mycotiques !

Ducruet et al. Neurosurgical Review, 2010

guillaume.saliou@chuv.ch

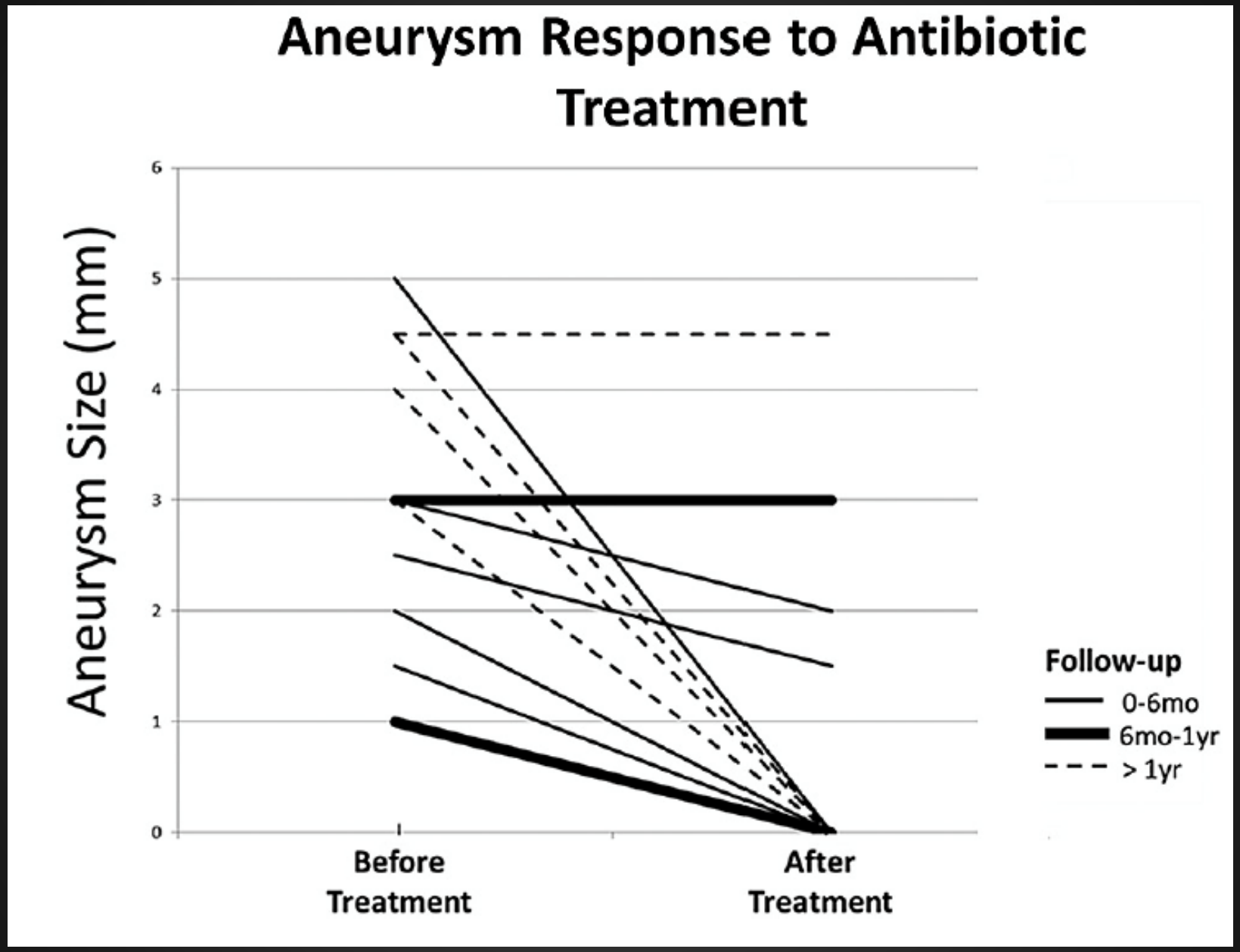

Allen et al. AJNR Am J Neuroradiol. Apr 2013

guillaume.saliou@chuv.ch

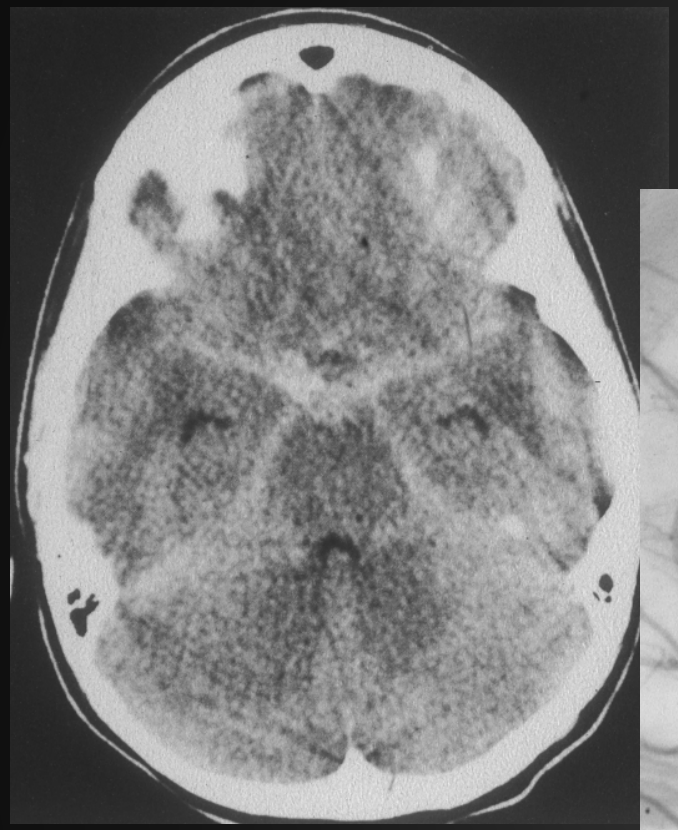

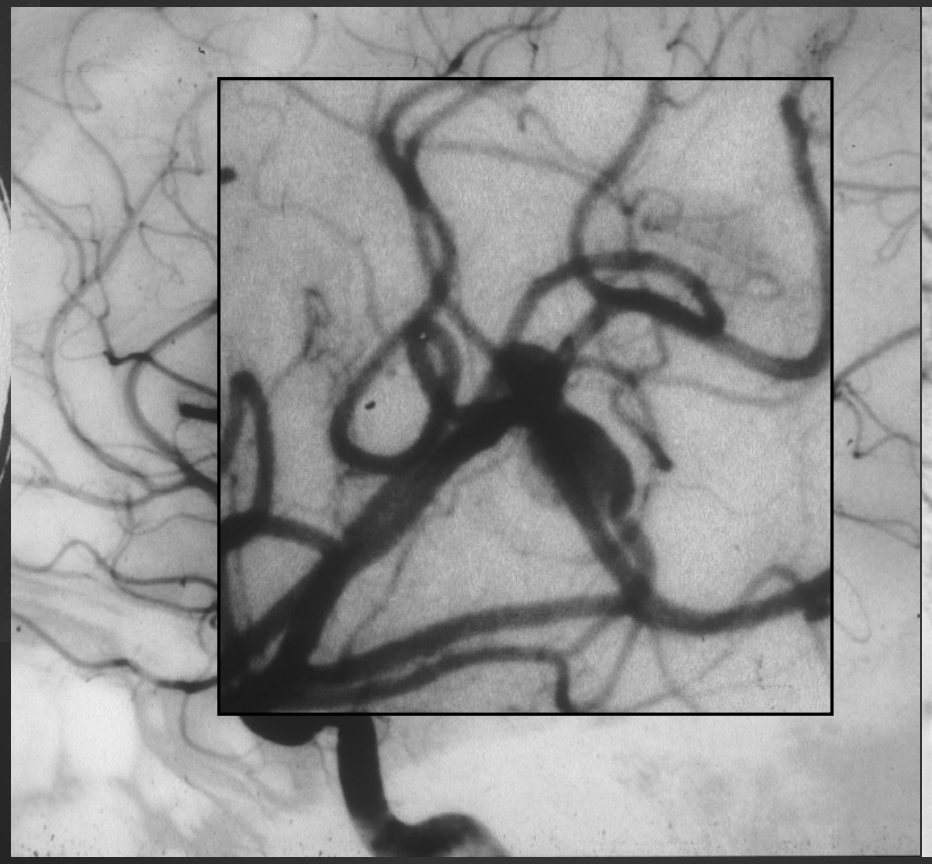

10 ans
TTT antibiotique

guillaume.saliou@chuv.ch

65 ans, endocardite

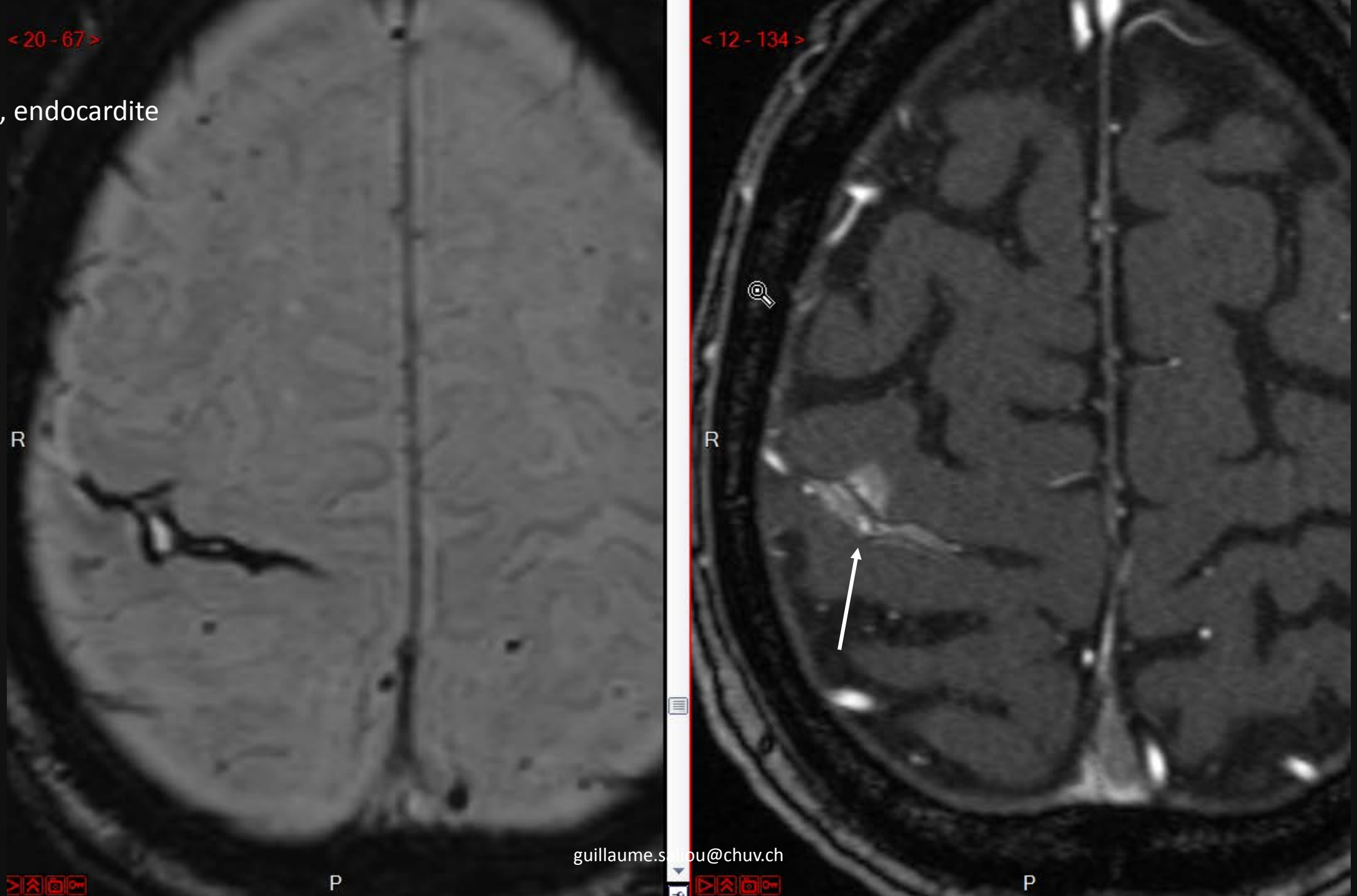

guillaume.saliou@chuv.ch

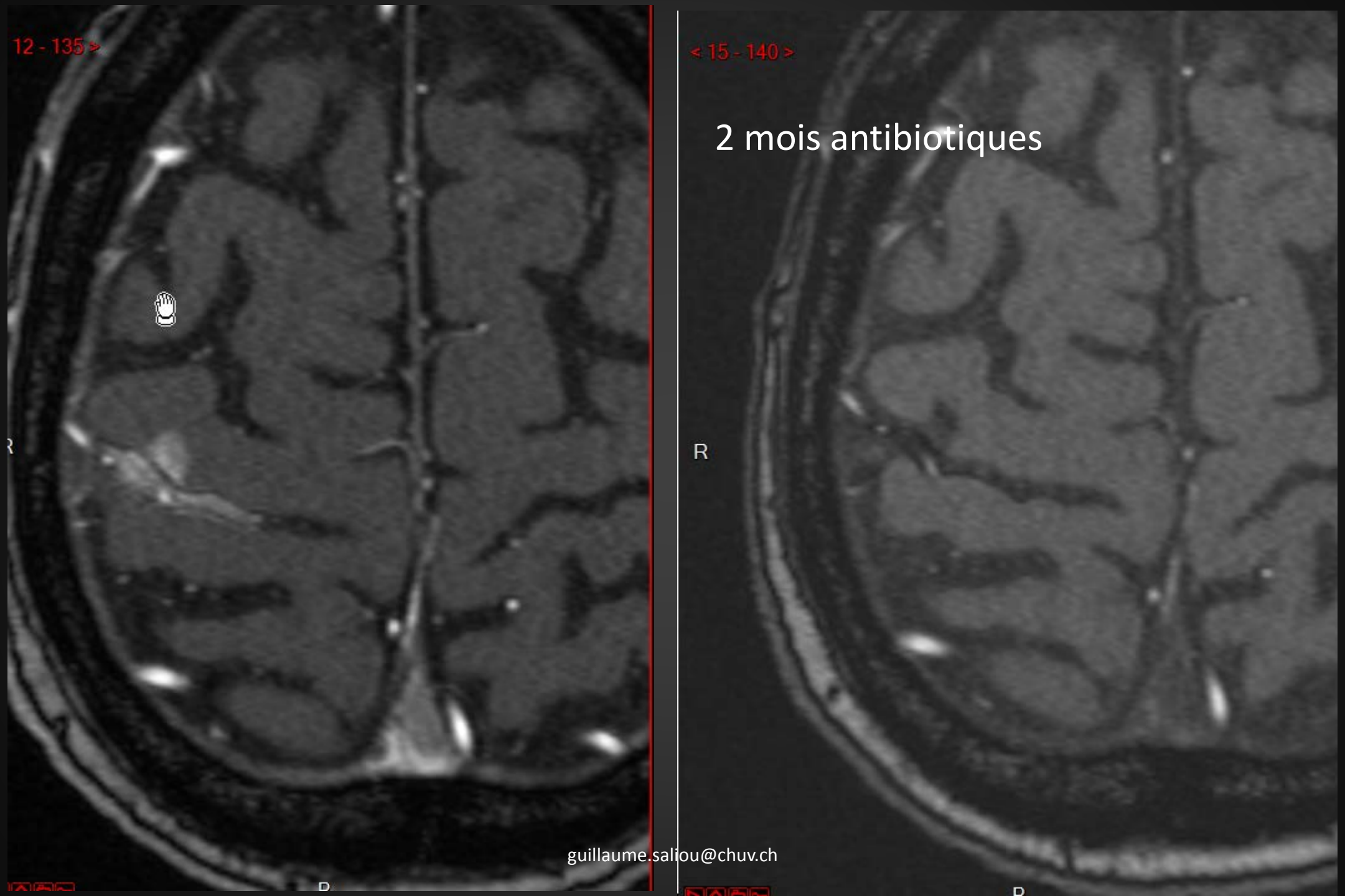

2 mois antibiotiques

guillaume.saliou@chuv.ch

35 ans, valve mécanique

Antibiotiques, contrôle à 1 an

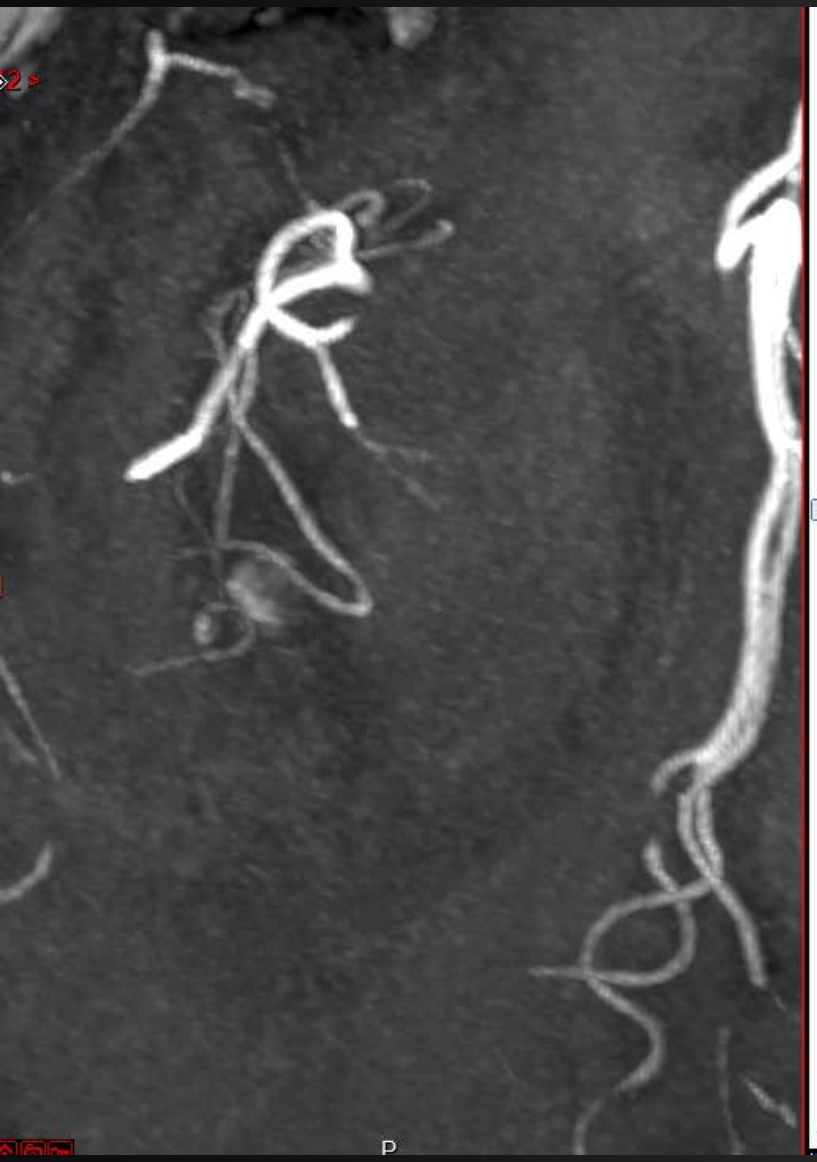

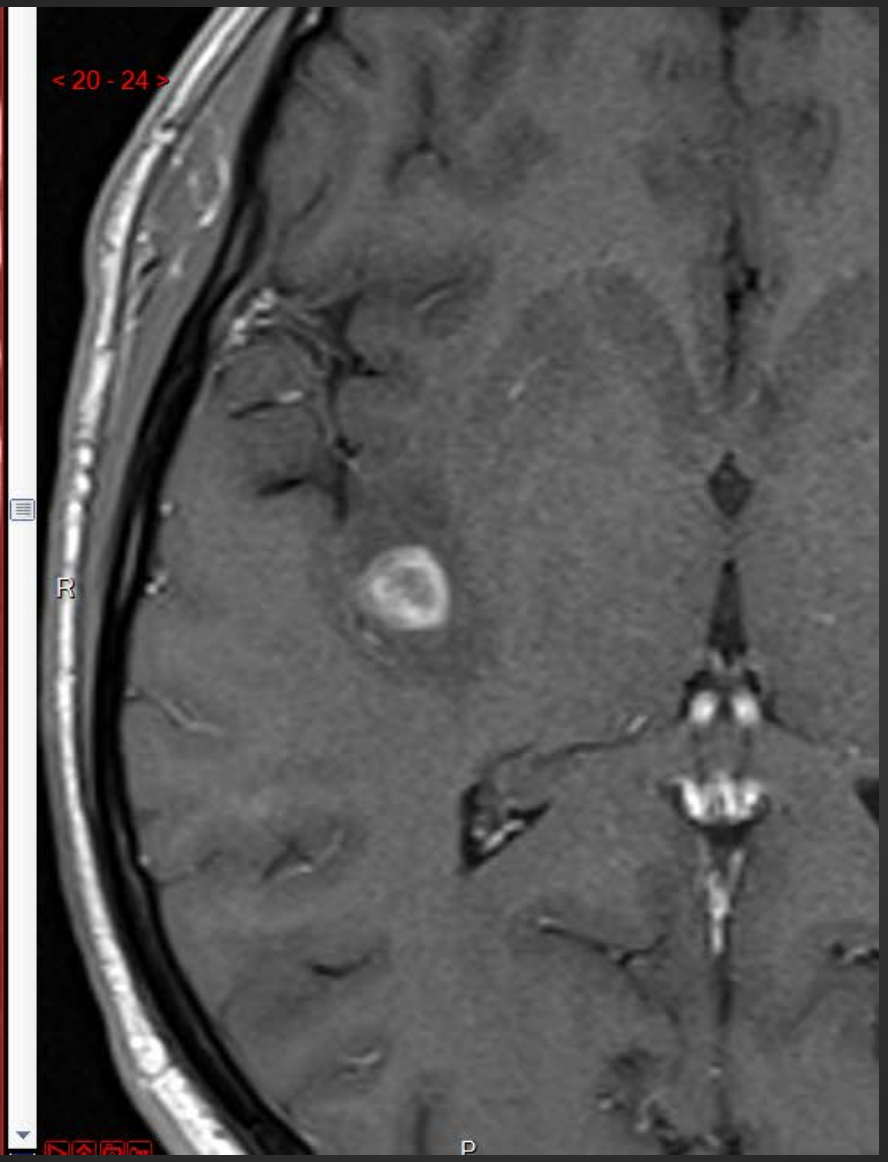

guillaume.saliou@chuv.ch

« Faux » anévrisme mycotique

Non rompu

Antibiotiques

Contrôle à 3 semaines

Disparition ou régression

Antibiotiques 3 semaines

Disparition

Stable ou augmentation

Stable ou augmentation

Proximaux

rompu

HSA ou Hématome non compressif

Hématome compressif

Région non éloquente

Région éloquente

Embolisation

Chirurgie

guillaume.saliou@chuv.ch

Thrombose veineuse cérébrale maligne

guillaume.saliou@chuv.ch

Stroke
Journal of the American Heart Association

Should Decompressive Surgery Be Performed in Malignant Cerebral Venous Thrombosis?

A Series of 12 Patients

Marie Théaudin, MD; Isabelle Crassard, MD; Damien Bresson, MD; Guillaume Saliou, MD, PhD; Pascal Favrole, MD; Katayoun Vahedi, MD; Christian Denier, MD, PhD; Marie-Germaine Bousser, MD, PhD

2010;41:727-731

guillaume.saliou@chuv.ch

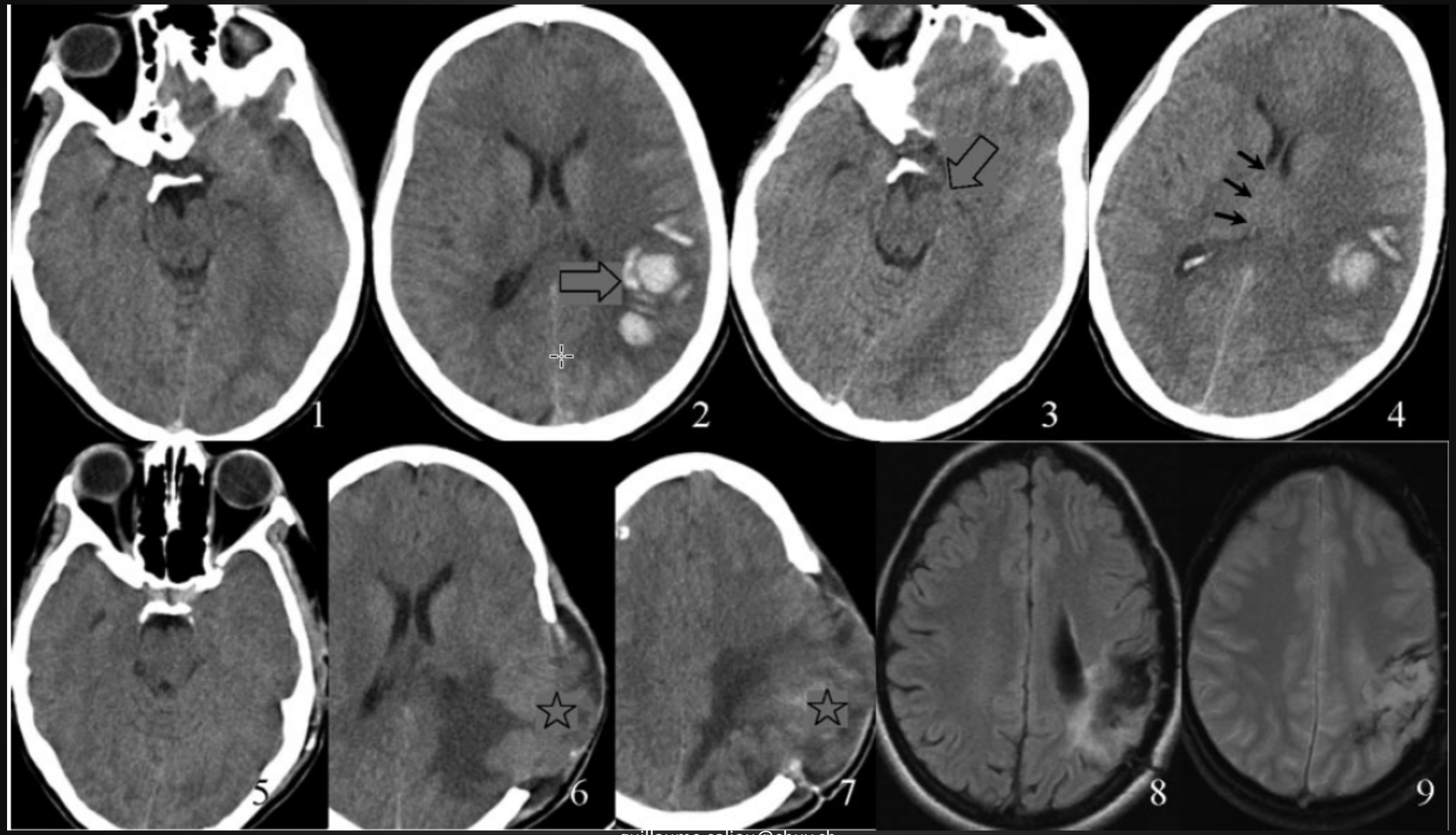

guillaume.saliou@chuv.ch

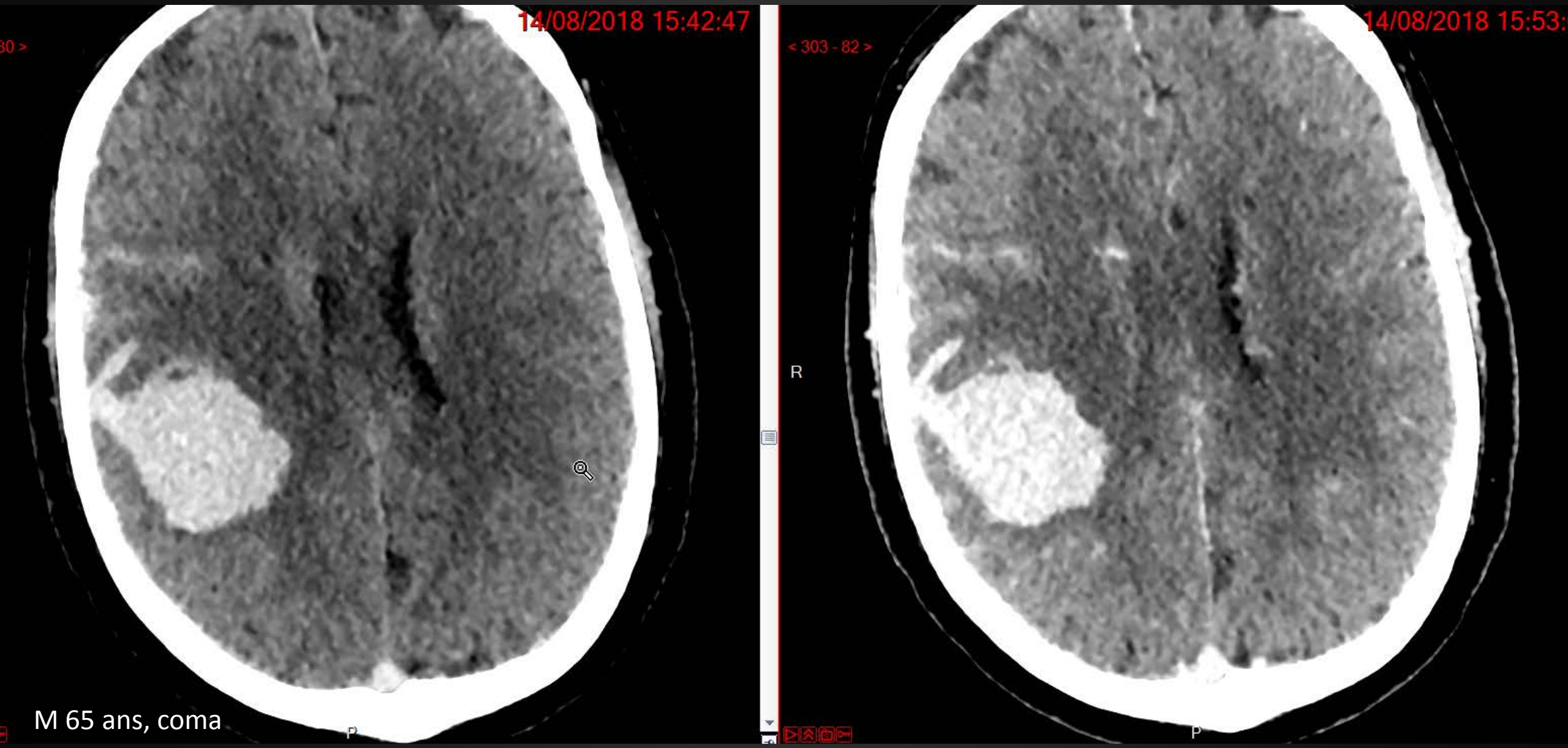

M 65 ans, coma

guillaume.saliou@chuv.ch

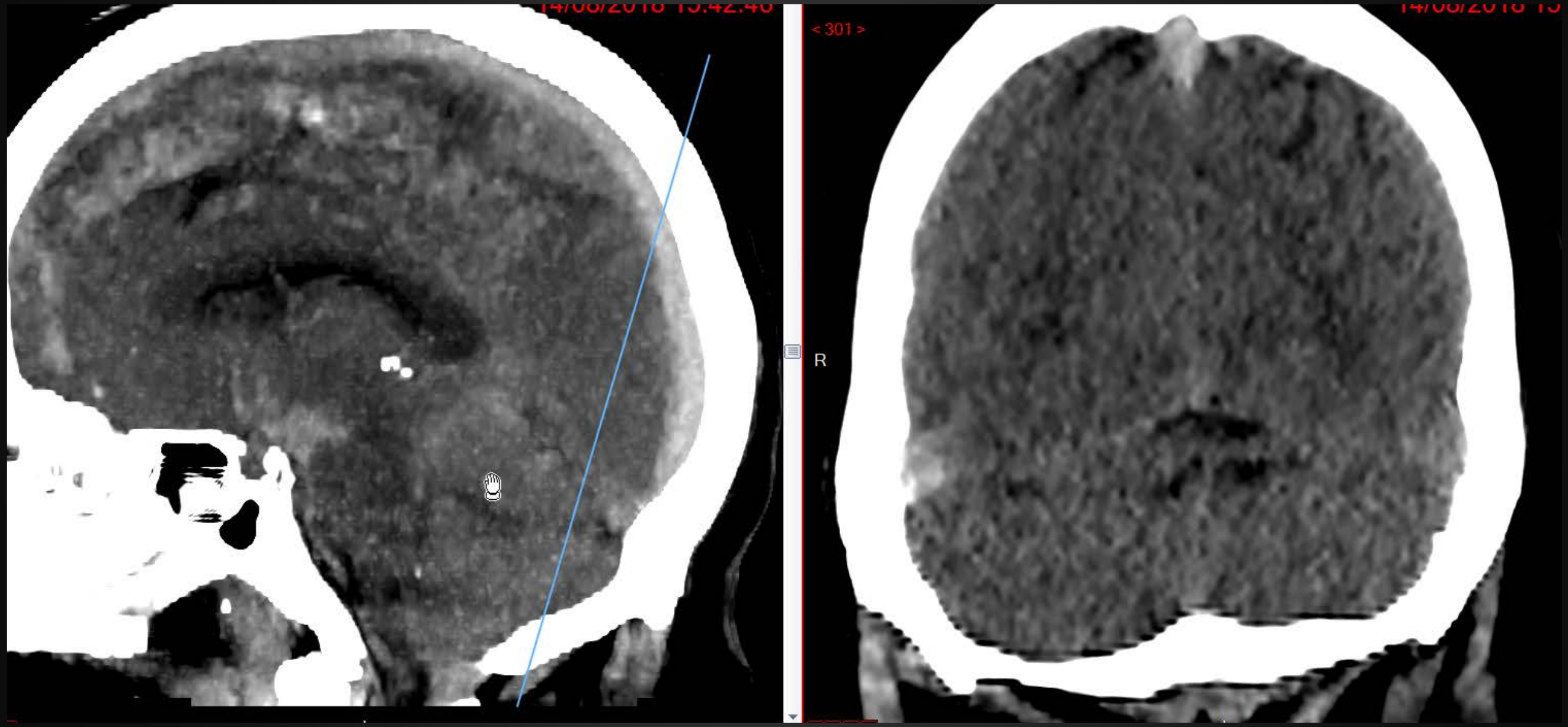

guillaume.saliou@chuv.ch

guillaume.saliou@chuv.ch

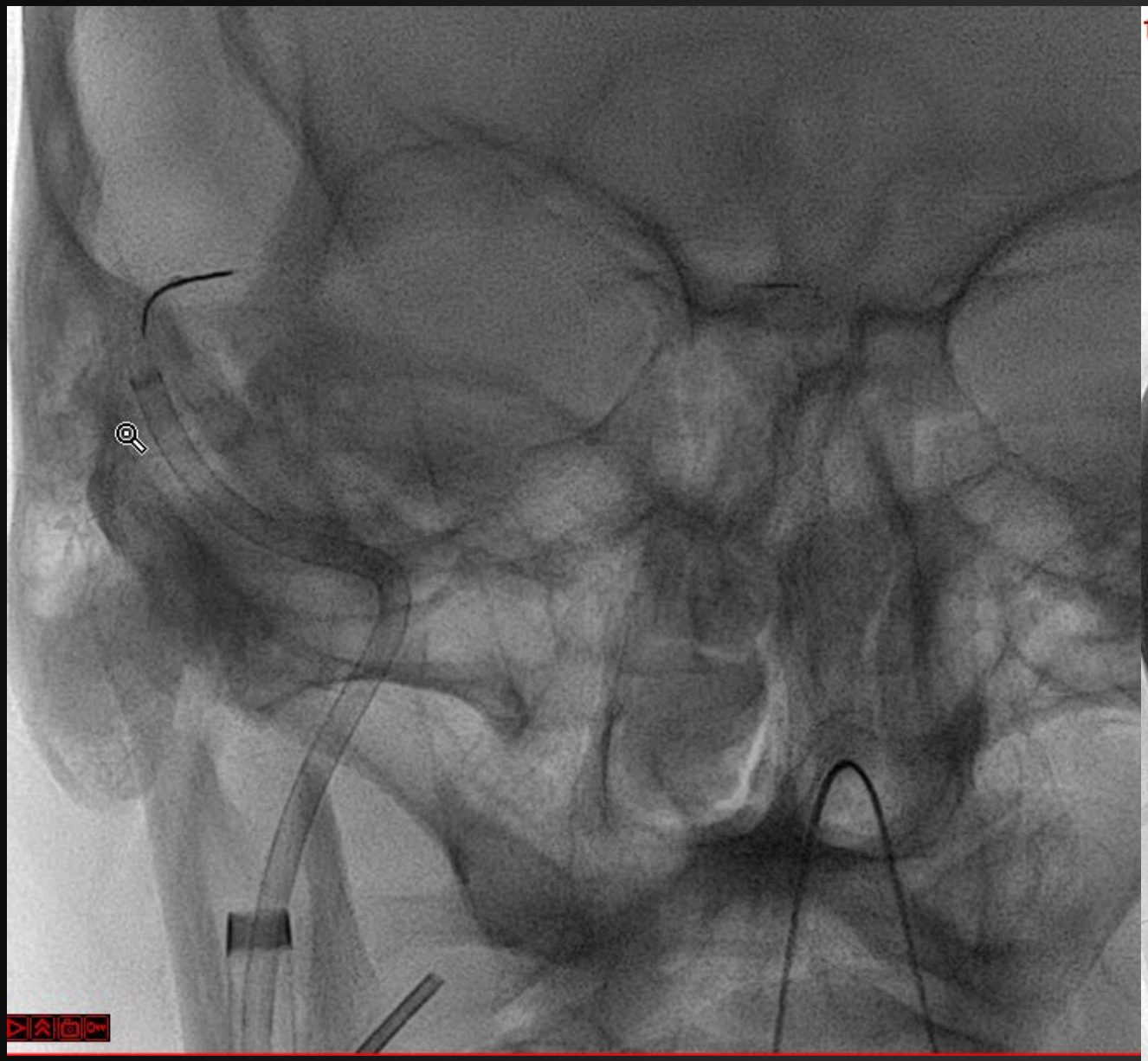

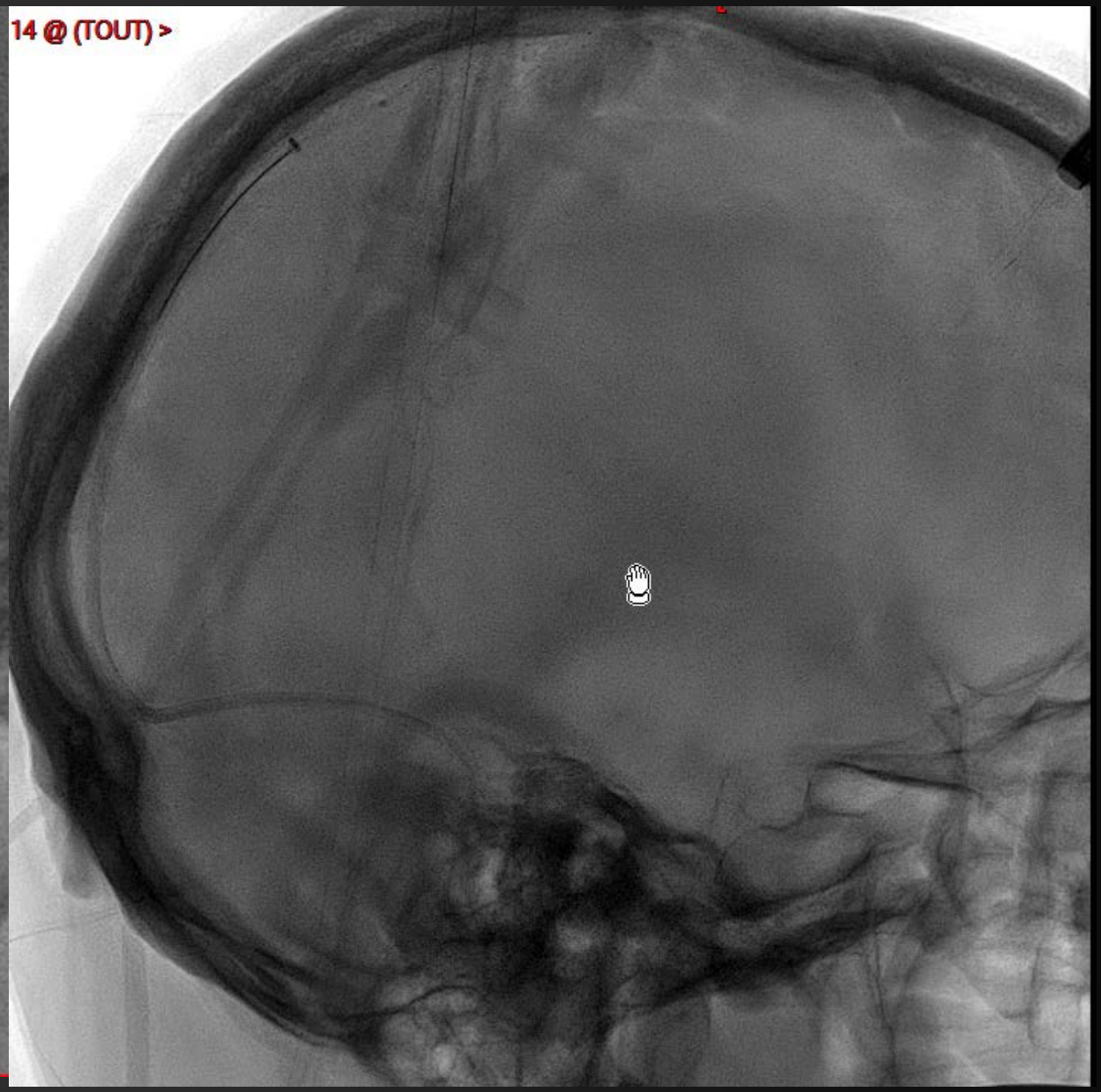

guillaume.saliou@chuv.ch

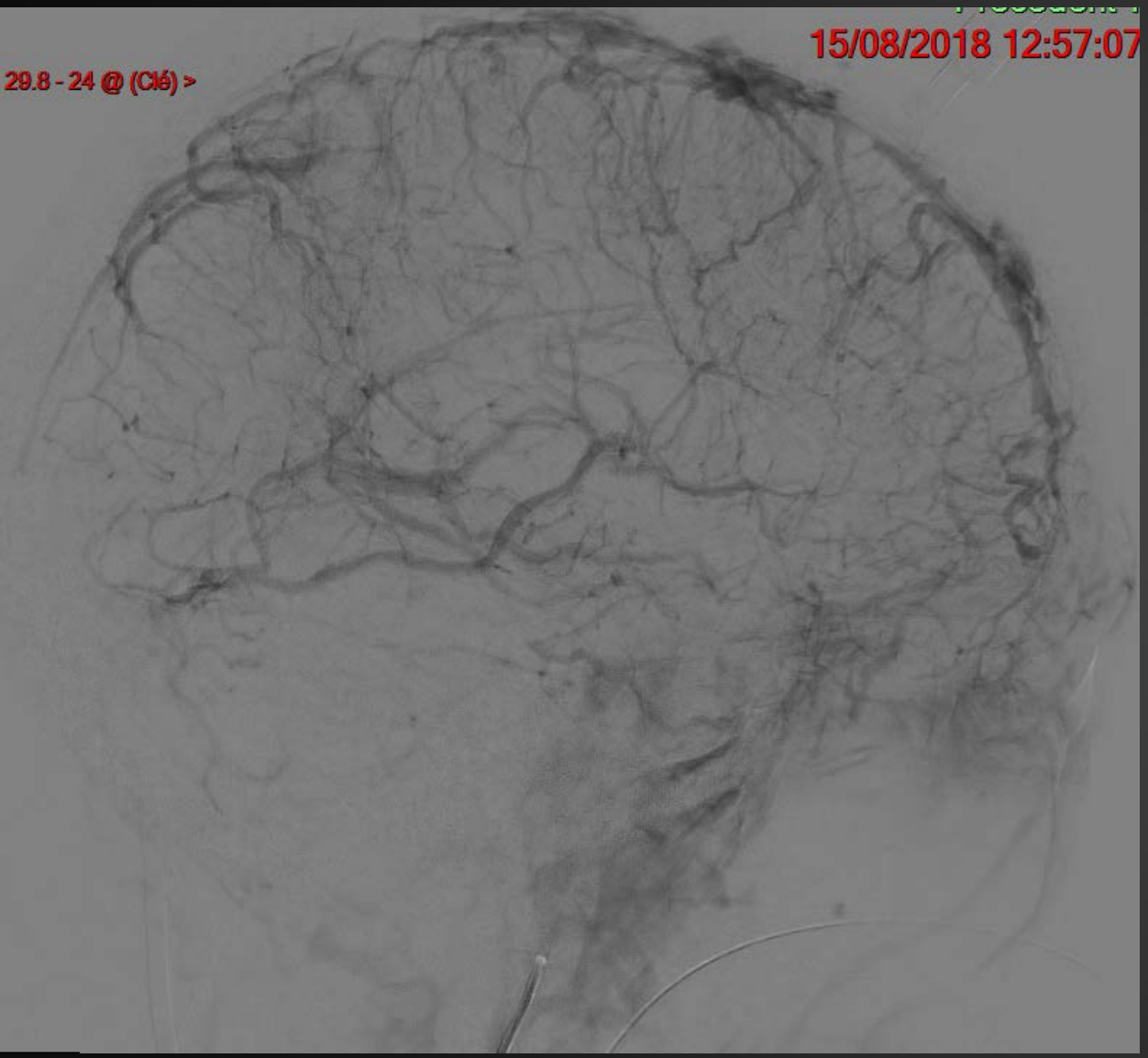

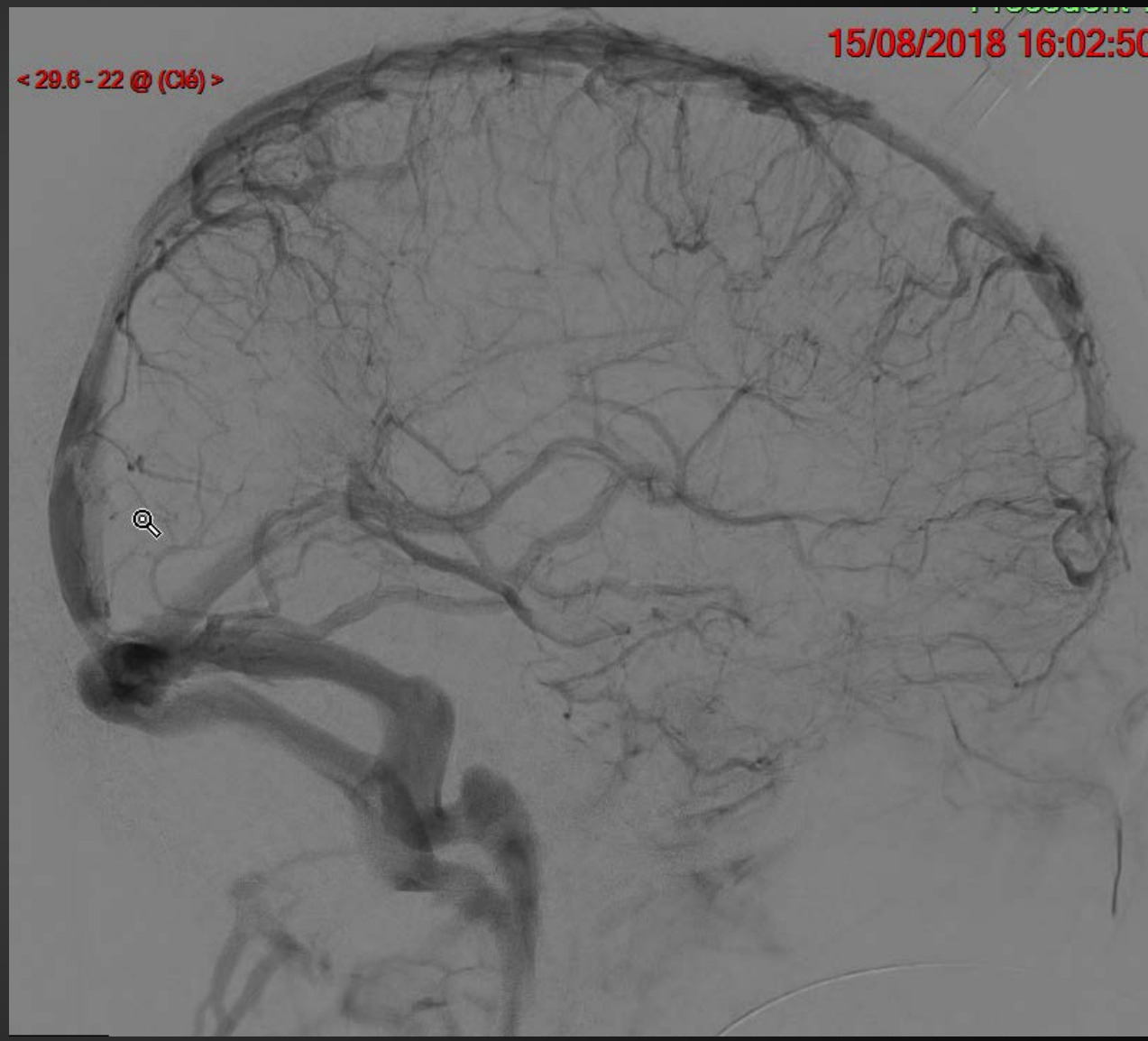

guillaume.saliou@chuv.ch

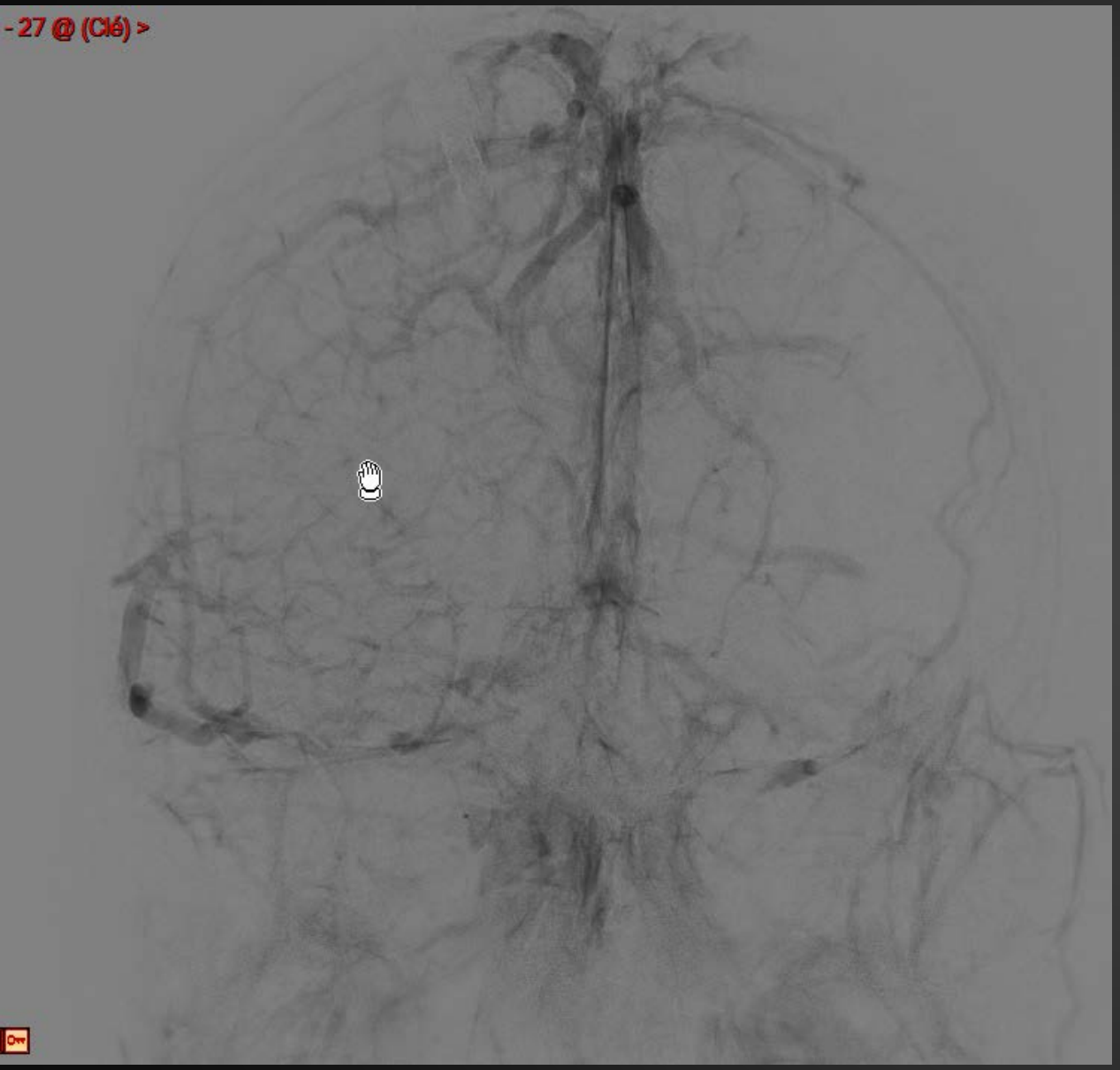

guillaume.saliou@chuv.ch

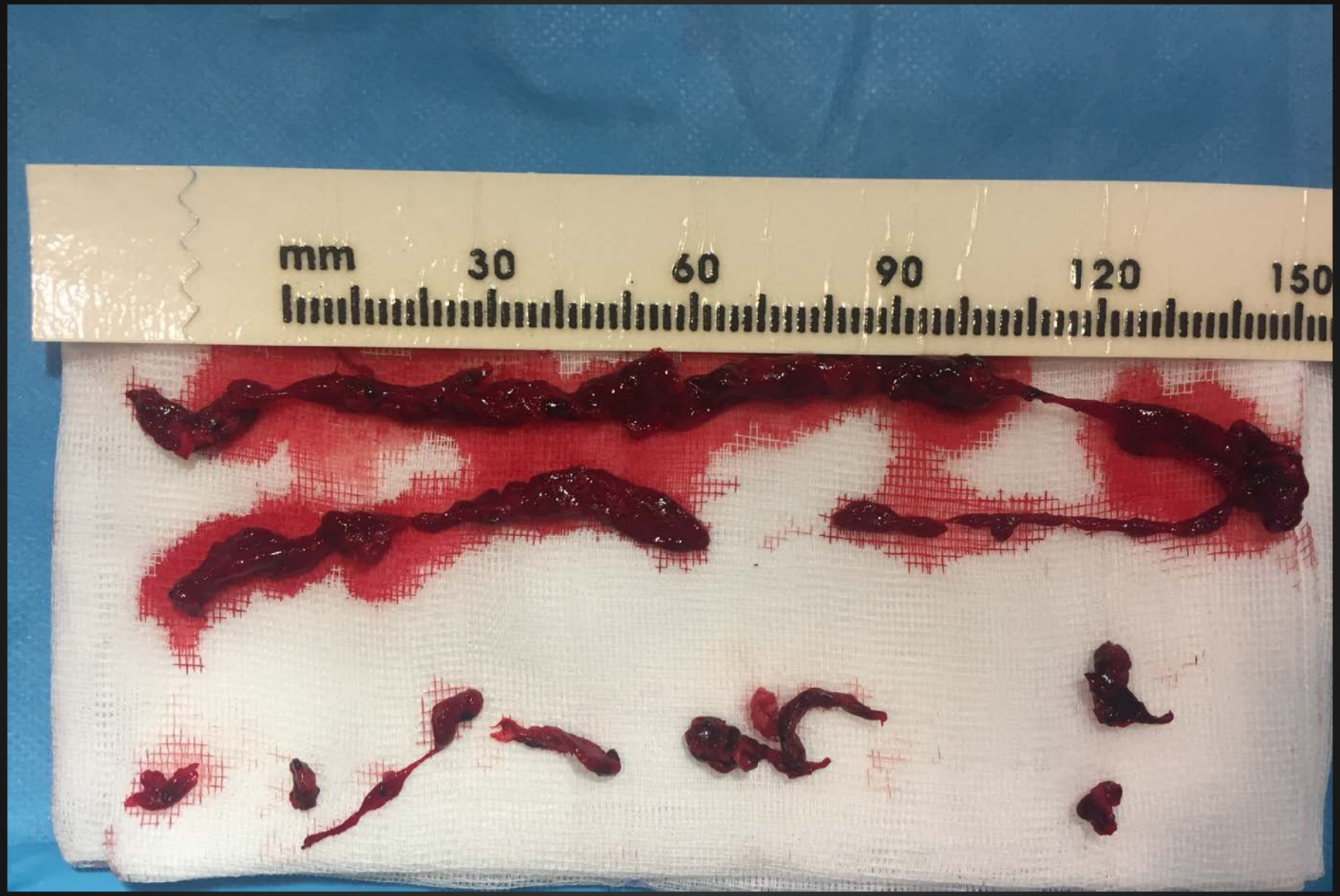

1 cm

guillaume.saliou@chuv.ch

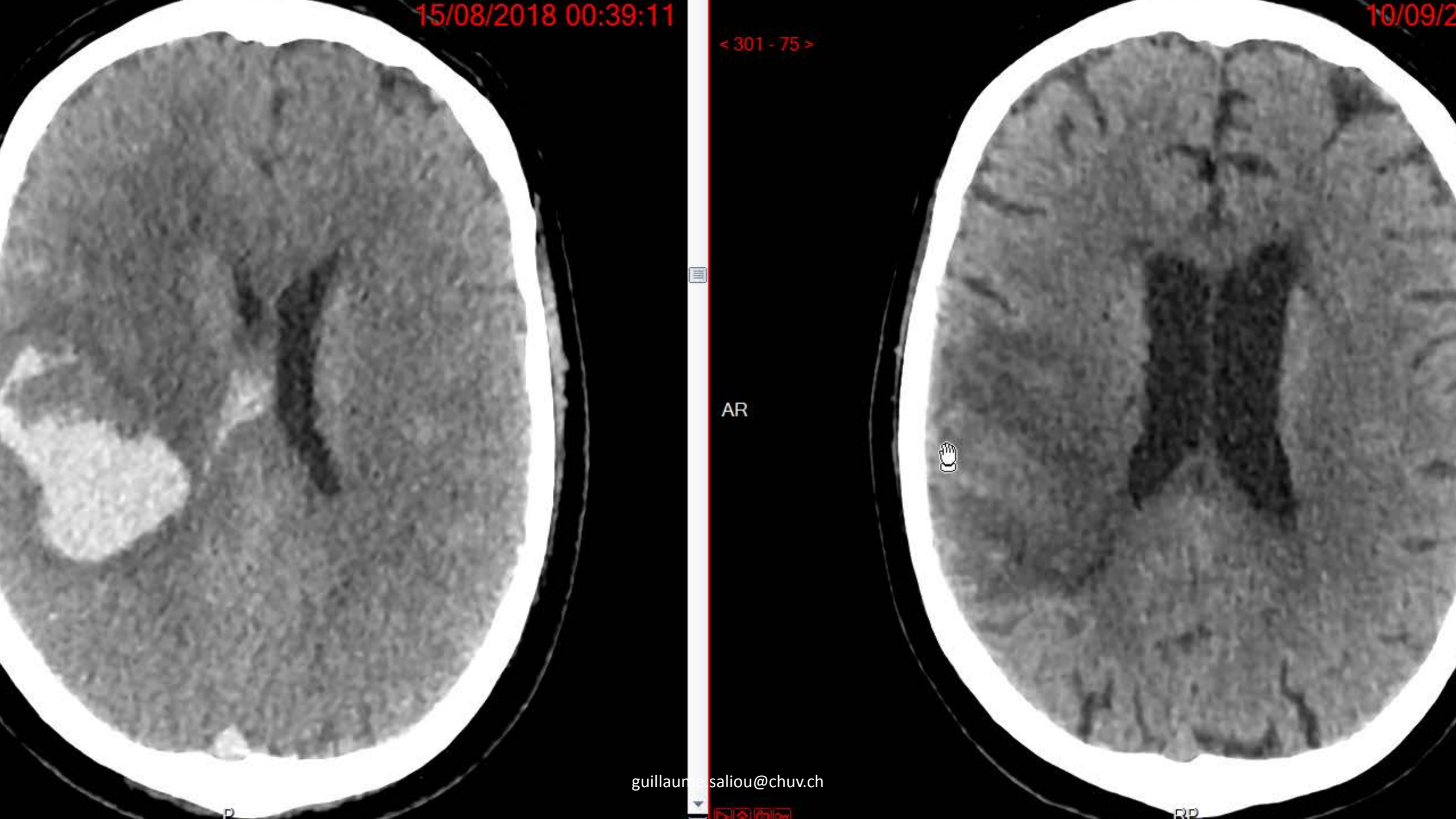

guillaume.saliou@chuv.ch

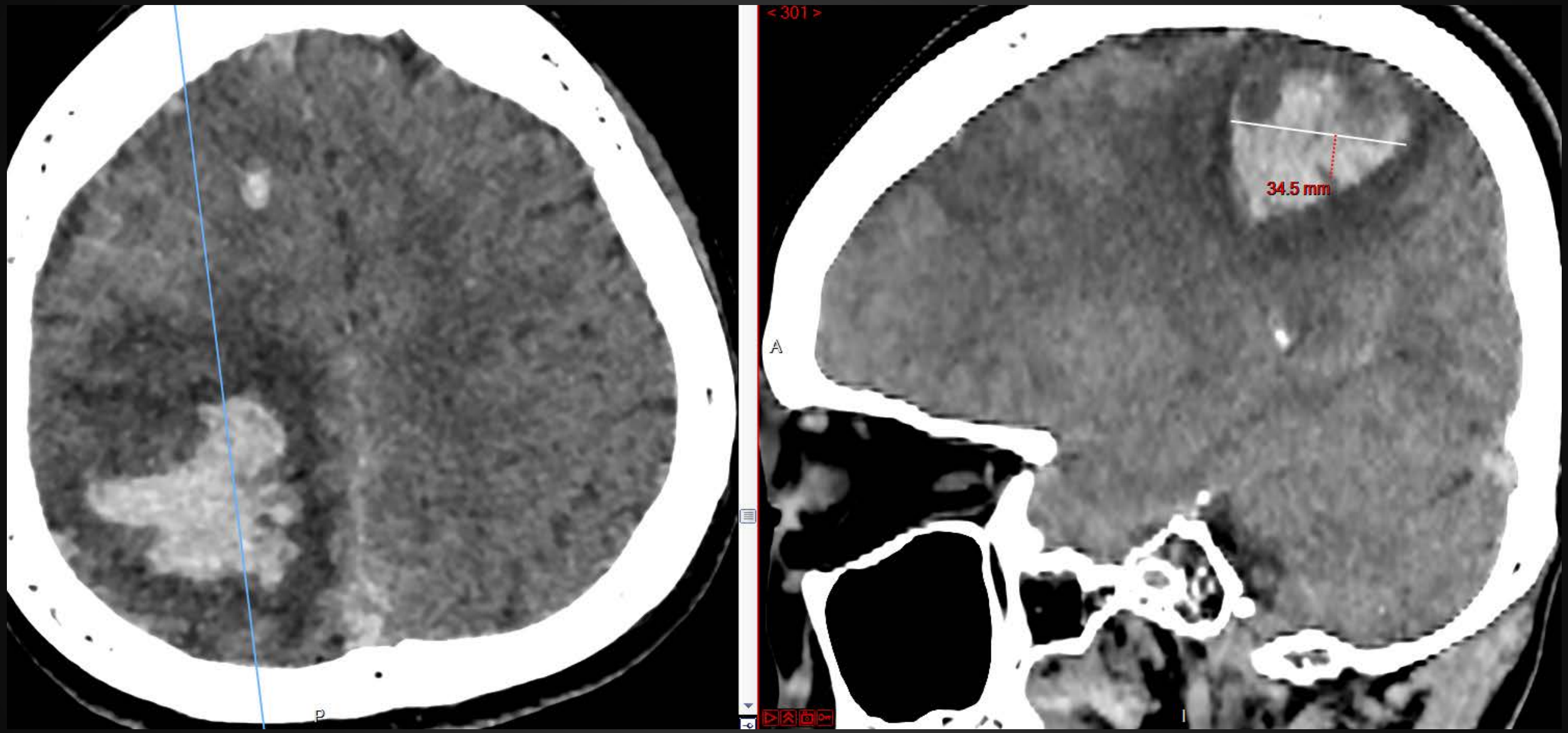

guillaume.saliou@chuv.ch

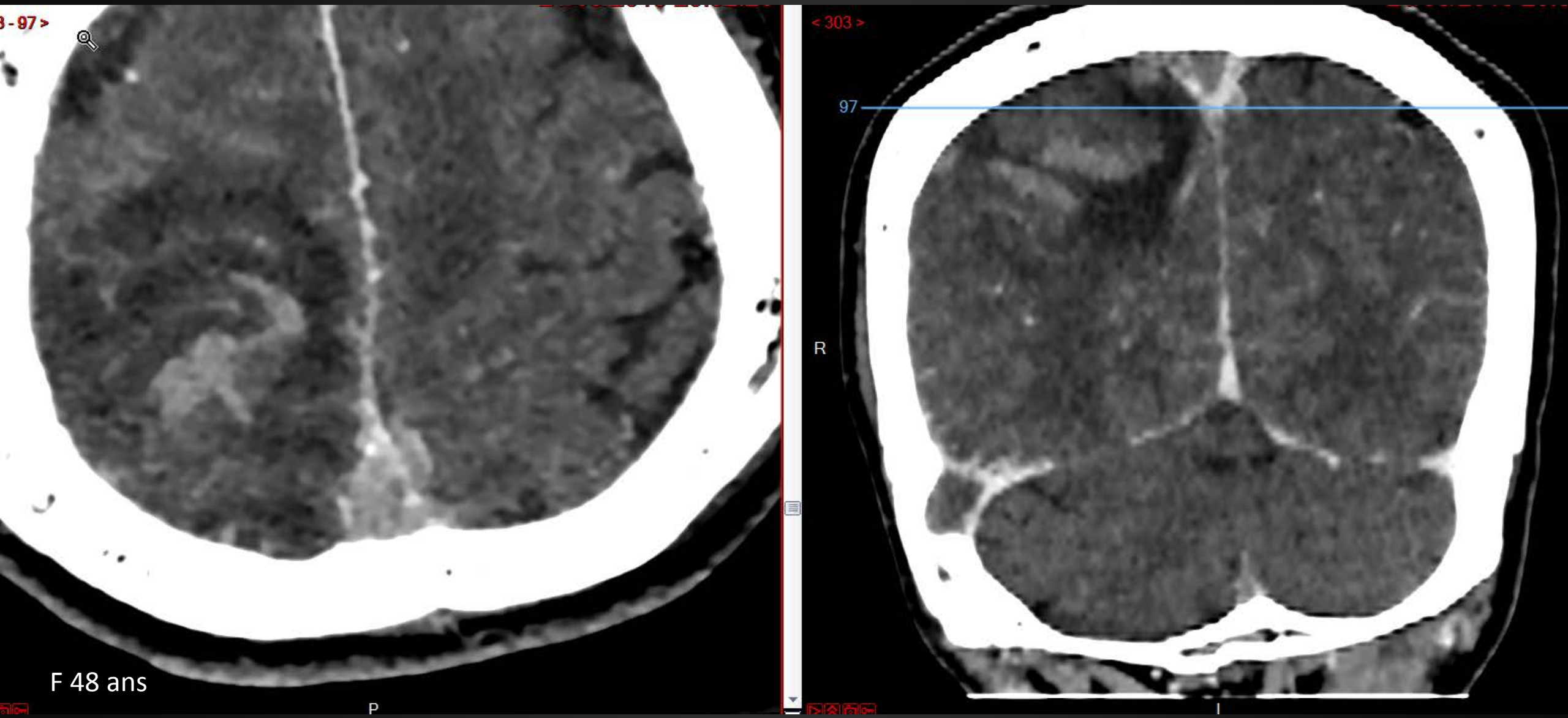

guillaume.saliou@chuv.ch

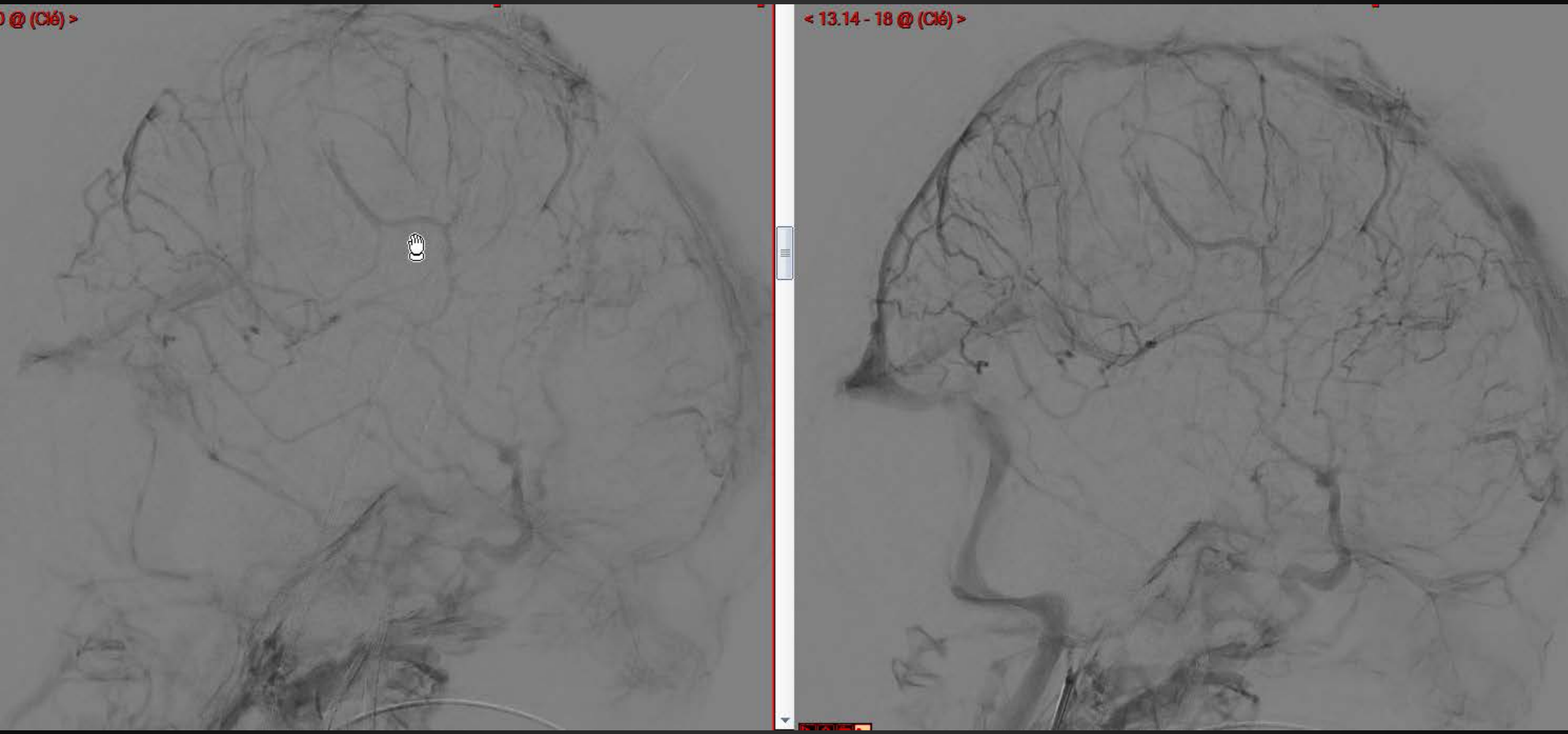

guillaume.saliou@chuv.ch

021.314.85.51

FACC

neurovasculaire@chuv.ch

***F**ilière de prise en charge des **A**névrismes **C**érébraux au **C**HUV*

Anévrismes cérébraux



HSA non traumatiques

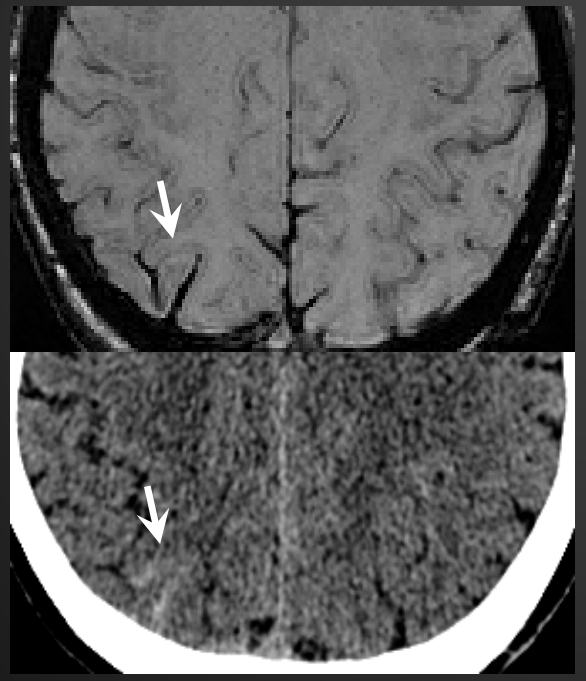

Hématomes non hypertensifs du sujet jeune

Malformations artérioveineuses

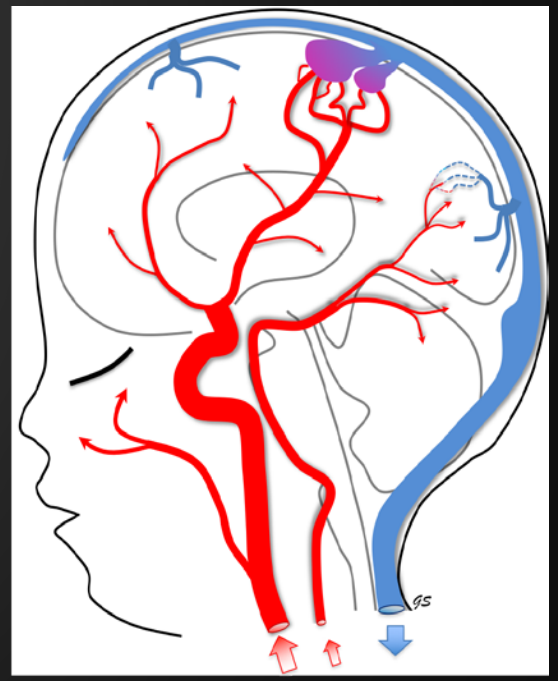

guillaume.saliou@chuv.ch