

J. Costes¹, M. Meyer², K. Casagrande¹, N. Schaefer², J. Prior², J. Delage², F. Sadeghipour³.

¹Pharmacy Department, Centre Hospitalier Universitaire Vaudois, Lausanne, Switzerland. ²Nuclear Medicine department, Centre Hospitalier Universitaire Vaudois, Lausanne, Switzerland. ³Centre de Recherche et d'Innovation en Sciences Pharmaceutiques Cliniques, Université de Lausanne, Switzerland.

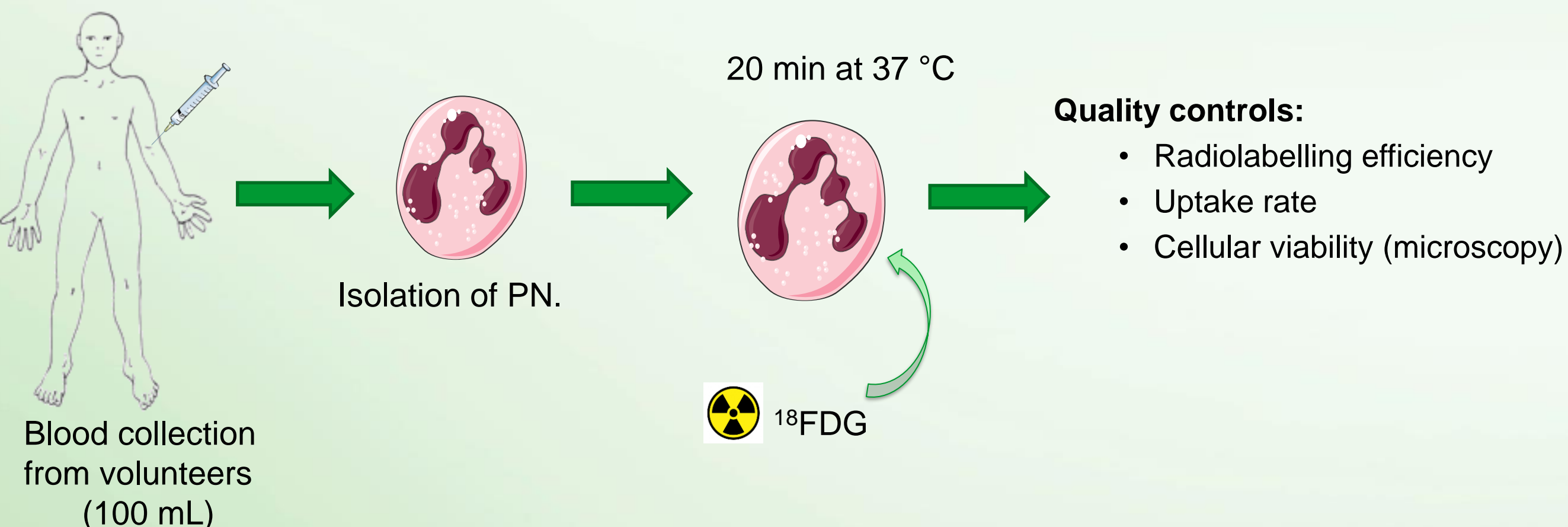
Introduction.

Radiolabelling autologous leucocytes (PN) scintigraphy with ^{99m}Tc-HMPAO is the gold standard for the diagnosis of infections to ensure a high specificity. However, the sensitivity can be low for several localizations. PET (Positron Emission Tomography) allows to achieve higher quality and sensitivity for imaging. We developed a PN labelling method with a PET tracer, the ¹⁸FDG.

Purpose.

The aim of the study was to assess the feasibility of this labelling technique.

Matériel et méthodes.



Elaboration of a clinical protocol with the physicians: acquisition times and definition of inclusion criteria.

Results and Discussion.

3 labelling tests were performed.

Radiolabelling efficiency	Uptake rate.	Cell viability.
78.2 %	91.6 %	98.0 %

Inclusion criteria chosen:

- Patients with acute infectious disease:
 - Leukocytes > 10G/L
 - VS > 5mm/h
- Precautions:
 - Patients fasted.
 - Drug interactions: anti-inflammatory and antibiotics have to be stopped.

Acquisition times: 2h and 3h post-injection.

Advantages of the method:

- Imaging can be done on a single day (imaging at 24h post-injection with scintigraphy).
- Higher sensitivity due to the PET.

Discussion: *in-vitro* validation of the method.

Further studies as stability of the labelling at 2h and 3h (acquisition times) have to be performed.

Conclusions

The PN labelling with ¹⁸FDG is a promising technique when scintigraphy lacks of sensitivity. Moreover, this method allows a high specificity.

A cohort of about 10 patients is expected for *in-vivo* validation.

This protocol could be extended to other indications such in cardiology to detect material infection (prosthetic valve, pace-maker).