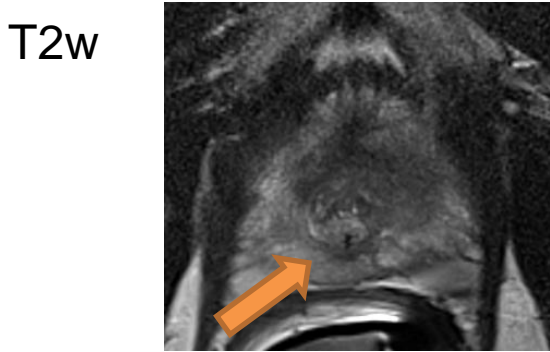
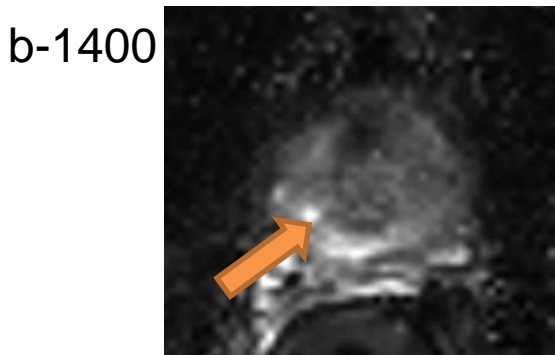


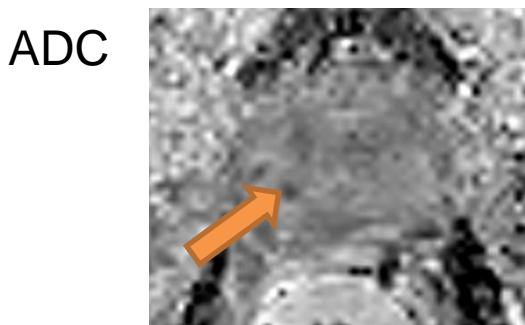
Case 2: Induration in the basal region, right-sided. PSA 4.4



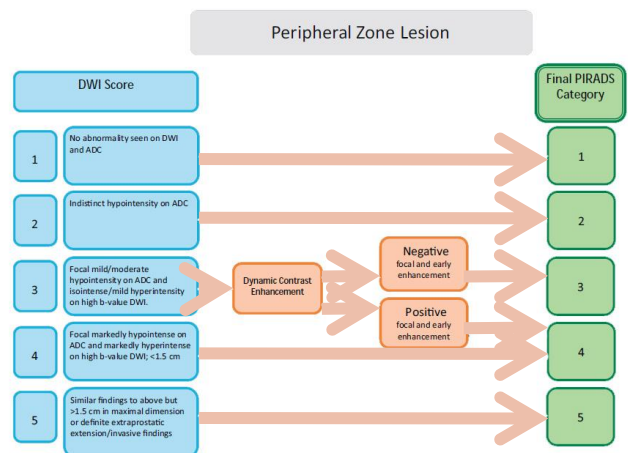
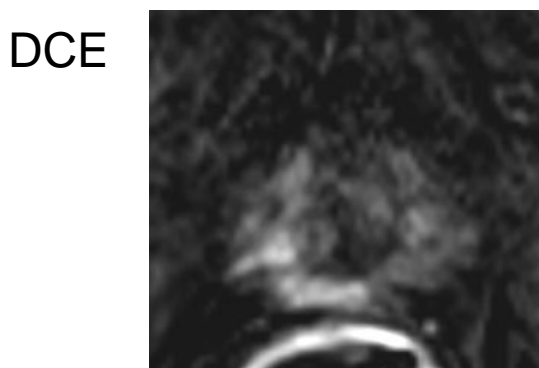Moderate heterogeneous diffuse hypointensity, wedge-shaped.



Markedly hyperintense tinny lesion, confined to the prostate in the apex, on the right side <1.5 cm.



Markedly hypointense tinny lesion, confined to the prostate in the apex, on the right side <1.5 cm.



In the PZ, dominant sequence is DWI → **PIRADS v2.0 = 4**