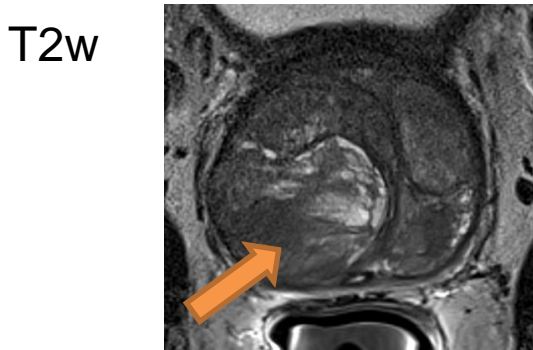
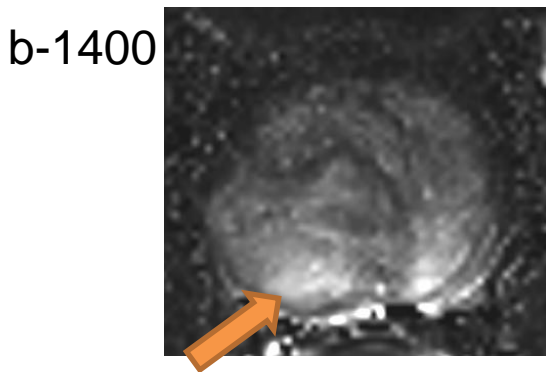


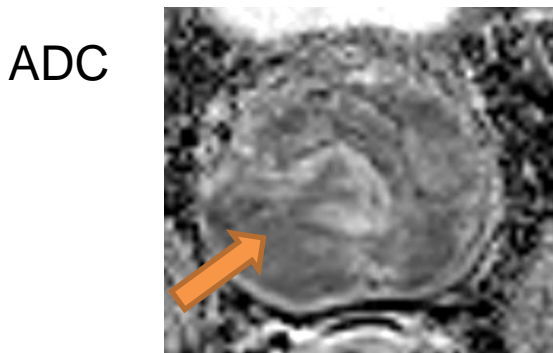
Case 3: Large prostate. Negative previous biopsy. PSA 8.0



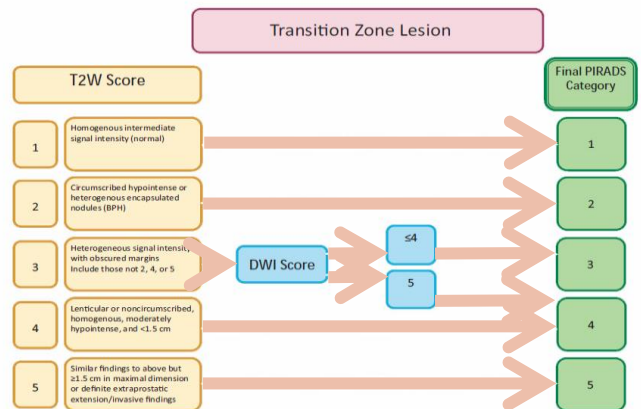
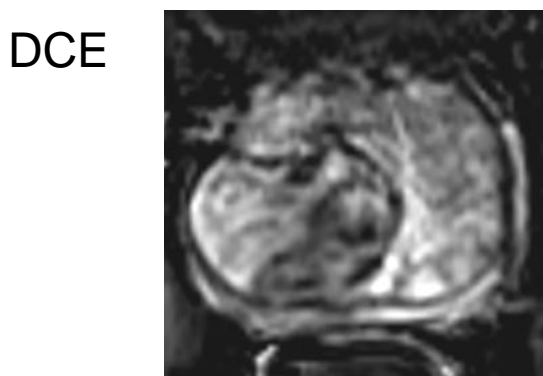
Non-circumscribed homogeneous hypointense area in the TZ, mid prostate, median region >1.5 cm



Markedly hyperintense region,



Markedly hypointense region



In the TZ, dominant sequence is T2w → **PIRADS v2.0 = 5**