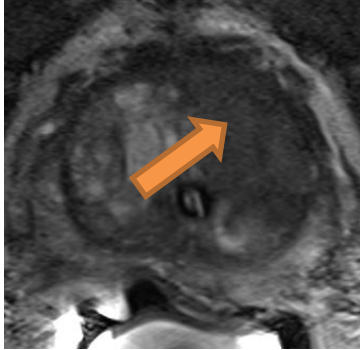


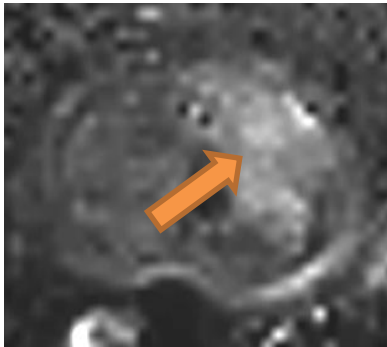
Case 4: Chronic urinary retention. Malignancy?

T2w



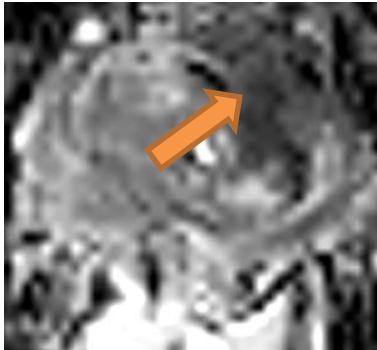
Non-circumscribed homogeneous hypointense area in the TZ, mid prostate, median region, anterior and posterior on the left >1.5 cm

b-1400



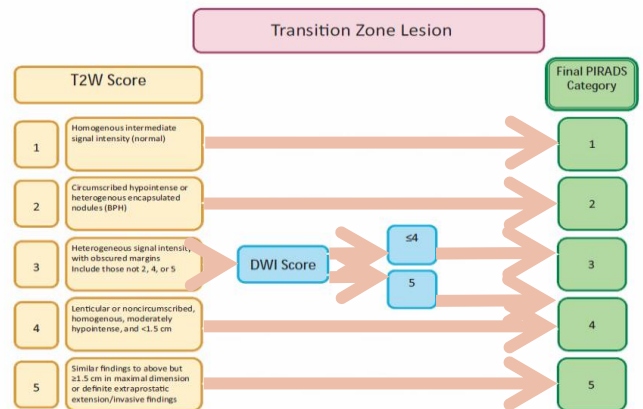
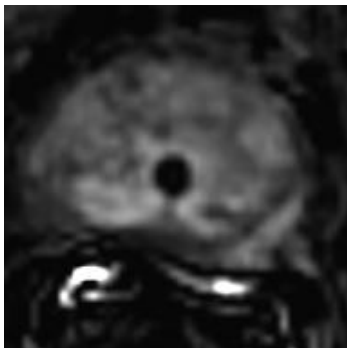
Markedly hyperintense region,

ADC



Markedly hypointense region

DCE



In the TZ, dominant sequence is T2w → **PIRADS v2.0 = 5**