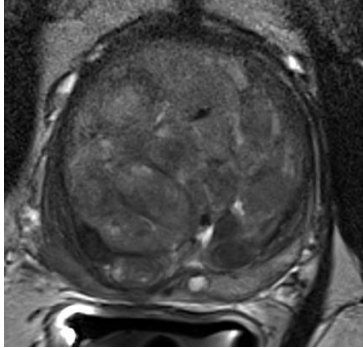


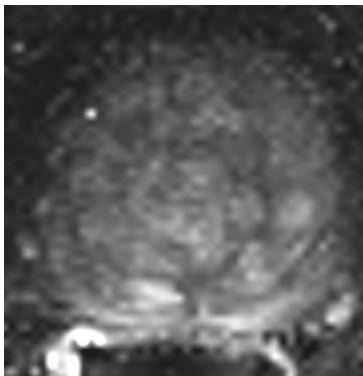
Case 5: Pathological PSA. No suspicious mass at DRE

T2w




Circumscribed heterogeneous encapsulated nodules, « organized chaos »

b-1400



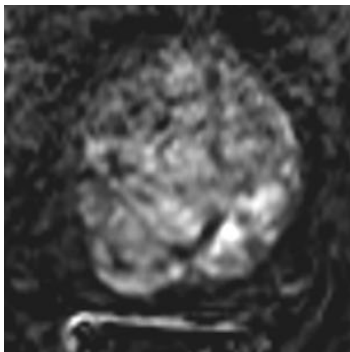
No abnormality

ADC



No abnormality

DCE



Circumscribed nodules, enlarged TZ  **PIRADS v2.0 = 2**