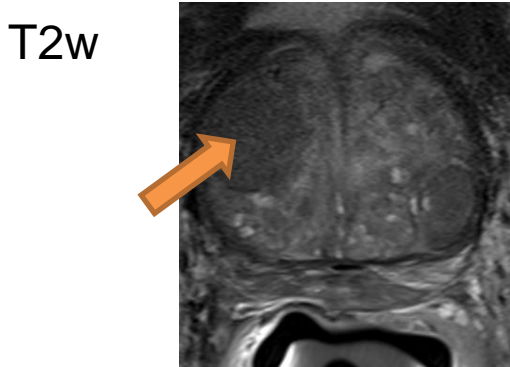
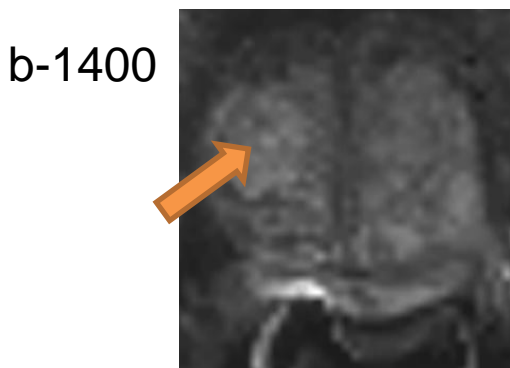


Case 6: Elevated PSA at 6.4

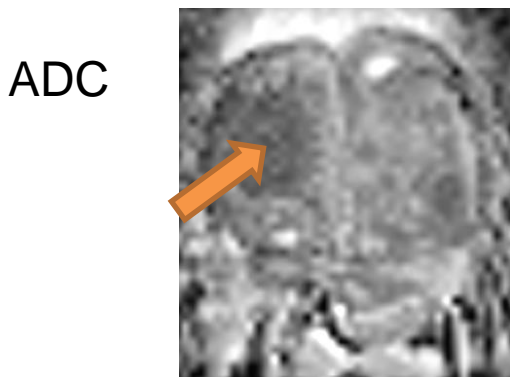


Heterogeneous signal intensity with obscured margins, TZ anterior right, mid prostate >1.5 cm

T2w : PIRADS v2.0 = 3

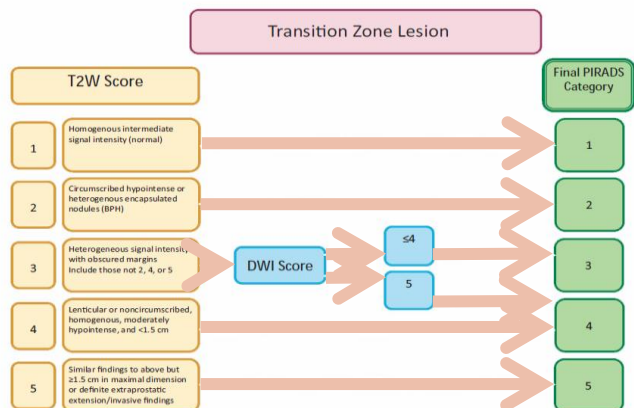
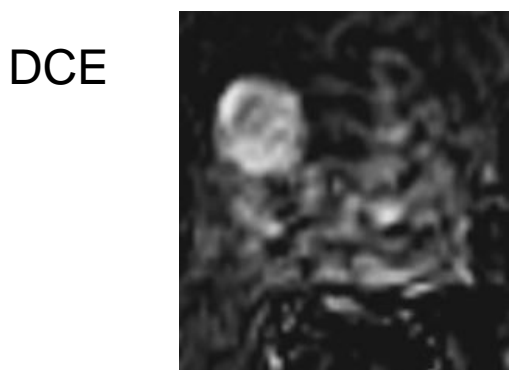

Markedly hyperintense lesion, in the same location,



Focal markedly hypointense region

DWI : PIRADS v2.0 = 5



3 on T2w, 5 on DWI

PIRADS v2.0 = 4